

### **Secondary Spontaneous pneumothorax in a sarcoidosis patient treated with endobronchial valve** **Islam Younes, Sherif El-Kattawy, Walaa Hammad, Juliet Kotys, Carlos Remolina**

#### INTRODUCTION:

Sarcoidosis is a multisystem inflammatory disorder with infiltration of noncaseating granulomas into various organs of the body. Pneumothorax is a potential but rare complication of late-stage sarcoidosis. Pneumothorax with persistent air leak after prolonged thoracostomy drainage is an indication for more aggressive procedures such as video-assisted thoracoscopy (VATS) pleurodesis. Endobronchial valve placement is an emerging technique that can be used in such patients, especially in poor operative candidates.

#### CASE PRESENTATION:

54-year-old African American female with 8 years sarcoidosis history, presented with sudden right chest pain and dyspnea. CXR and CT chest showed right-sided tension pneumothorax. Previous CT chest images showed innumerable cysts and bullae replacing the upper lobes and reticulonodular pattern of the lower lobes (Figure 1). A right chest tube was inserted but with persistent air leak for more than 7 days and worsening pneumothorax (Figure 2). Two endobronchial valves were then placed in the right upper lobe bronchi with complete re-expansion of the lung and resolution of the pneumothorax in 6 days (Figure 3). The patient was then discharged.

#### DISCUSSION:

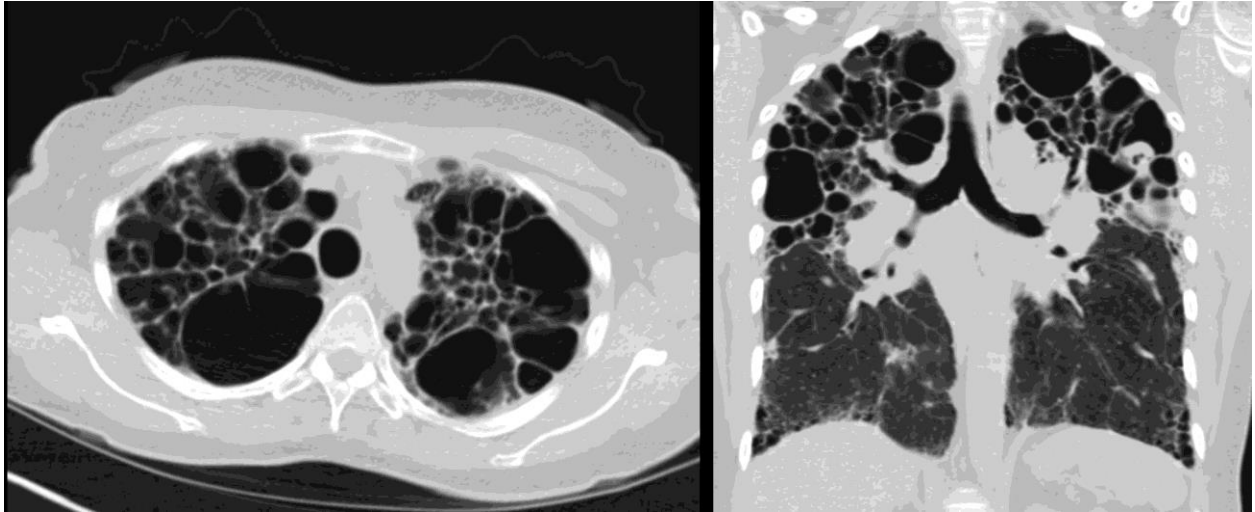
Pneumothorax occurs only in 2 % of sarcoidosis patients. It usually occurs due to rupture of subpleural bullae or necrosis of subpleural granuloma. Pneumothorax with persistent air leak despite chest tube drainage is an indication for VATS pleurodesis or stapling of the air leak. Endobronchial valves are emerging devices with FDA approval for only emphysema reduction in COPD patients or prolonged air leak after lung surgery. Our case showed complete resolution of the air leak and pneumothorax after endobronchial valve placement in a patient with a secondary spontaneous pneumothorax.

#### CONCLUSION:

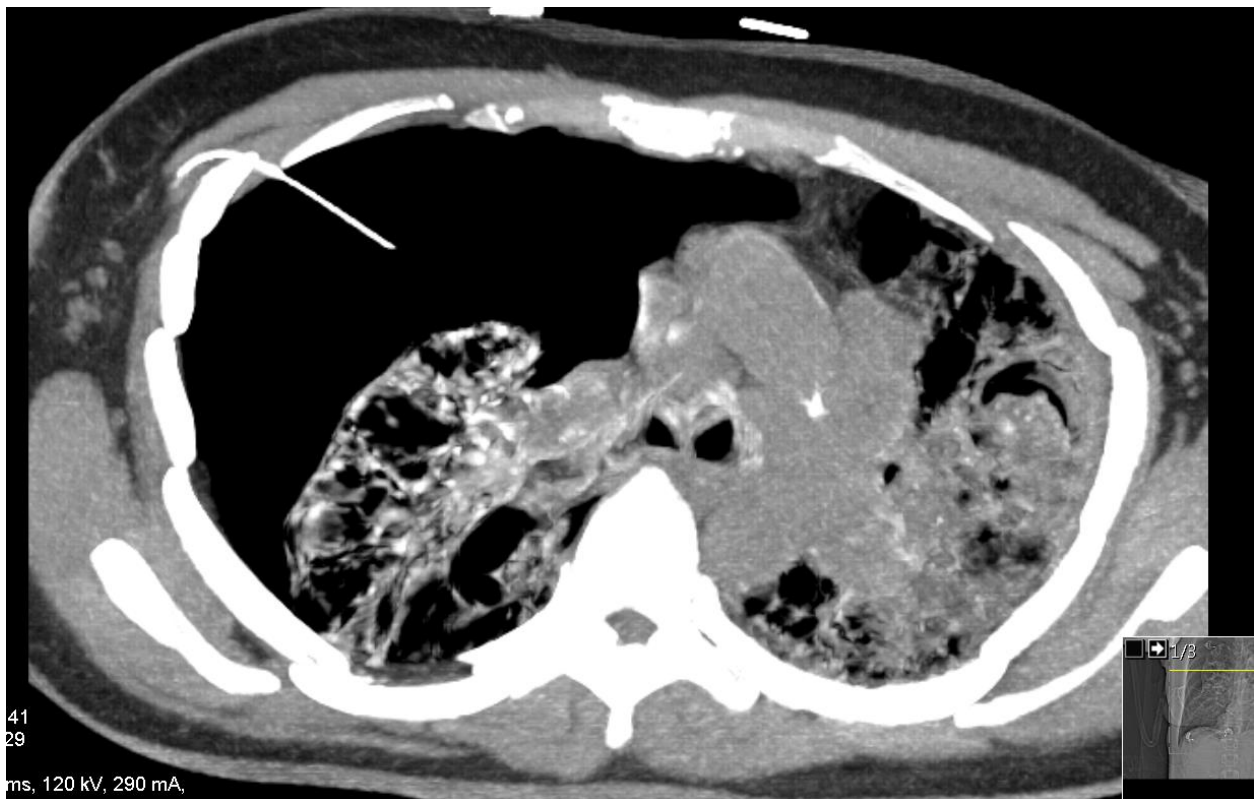Further studies are needed to be conducted for the use of endobronchial valves for other indications besides emphysematous patients and post lung surgery. It has the potential to become an invaluable resource for secondary spontaneous pneumothorax, especially in poor surgical candidates.

## Abstract 91

**Figure 1:** CT chest showing cystic changes and blebs in the bilateral upper lobes and interstitial thickening with subpleural cystic changes at the lung bases.



**Figure 2:** CT chest showing worsening right tension pneumothorax despite chest tube insertion.



**Figure 3:** CXR and CT chest showing resolving of the pneumothorax after placement of the endobronchial valves (arrows).

